

Brain anatomy of persistent violent offenders: More rather than less

Jari Tiihonen^{a,b,*}, Roberta Rossi^c, Mikko P. Laakso^{d,e}, Sheilagh Hodgins^f, Cristina Testa^g, Jorge Perez^h, Eila Repo-Tiihonen^a, Olli Vaurio^a, Hilikka Soininen^d, Hannu J. Aronen^{i,j,k}, Mervi Könönen^{e,l}, Paul M. Thompson^m, Giovanni B. Frisoniⁿ

^aDepartment of Forensic Psychiatry, Niuvanniemi Hospital, University of Kuopio, Kuopio, Finland

^bDepartment of Clinical Physiology, Kuopio University Hospital, Kuopio, Finland

^cLaboratory of Epidemiology Neuroimaging, and Telemedicine and Biological Psychiatric Unit, IRCCS San Giovanni di Dio- FBF, Brescia, Italy

^dDepartment of Neurology, Kuopio University Hospital, Kuopio, Finland

^eDepartment of Clinical Radiology, Kuopio University Hospital, Kuopio, Finland

^fInstitute of Psychiatry, King's College, University of London, UK

^gLaboratory of Epidemiology Neuroimaging, and Telemedicine, IRCCS San Giovanni di Dio-FBF, Brescia, Italy; Machine Vision Laboratory, Department of Mathematics and Computer Science, University of Udine, Udine, Italy

^hBiological Psychiatry Unit and Double Diagnosis Ward, IRCCS San Giovanni di Dio- FBF, Brescia, Italy

ⁱFunctional Brain Imaging Unit, Helsinki University Central Hospital, Helsinki Brain Research Center, Helsinki, Finland

^jCentre for Military Medicine, Finnish Defence Forces, Helsinki, Finland

^kDepartment of Diagnostic Radiology, University of Turku, Turku, Finland

^lDepartment of Clinical Neurophysiology, Kuopio University Hospital, Kuopio, Finland

^mLaboratory of Neuroimaging and Brain Mapping Division, Department of Neurology, University of California, Los Angeles, USA

ⁿPsychogeriatrics Ward and Laboratory of Epidemiology Neuroimaging and Telemedicine, IRCCS San Giovanni di Dio FBF, Brescia, Italy;

AFaR — Associazione Fatebenefratelli per la Ricerca, Rome, Italy

Received 20 February 2007; received in revised form 30 May 2007; accepted 26 August 2007

Abstract

Most violent crimes in Western societies are committed by a small group of men who display antisocial behavior from an early age that remains stable across the life-span. It is not known if these men display abnormal brain structure. We compared regional brain volumes of 26 persistently violent offenders with antisocial personality disorder and substance dependence and 25 healthy men using magnetic resonance imaging volumetry and voxel-based morphometry (VBM). The violent offenders, as compared with the healthy men, had markedly larger white matter volumes, bilaterally, in the occipital and parietal lobes, and in the left cerebellum, and larger grey matter volume in right cerebellum (effect sizes up to 1.24, $P < 0.001$). Among the offenders, volumes of these areas were not associated with psychopathy scores, substance abuse, psychotropic medication, or global IQ scores. By contrast, VBM analyses of grey matter revealed focal, symmetrical, bilateral areas of atrophy in the postcentral gyri, frontopolar cortex, and orbitofrontal cortex among the offenders as compared with the healthy men (z -scores as high as 5.06). Offenders with

* Corresponding author. Department of Forensic Psychiatry, University of Kuopio, Niuvanniemi Hospital, FI-70240 Kuopio, Finland. Tel: +358 17 203 111; fax: +358 17 203 494.

E-mail address: jari.tiihonen@niuva.fi (J. Tiihonen).

psychopathy showed the smallest volumes in these areas. The larger volumes in posterior brain areas may reflect atypical neurodevelopmental processes that underlie early-onset persistent antisocial and aggressive behavior.

© 2007 Elsevier Ireland Ltd. All rights reserved.

Keywords: Antisocial; Psychopathy; MRI; Volumetry; Aggression; Violence

1. Introduction

Approximately 5% of males are characterized by a pattern of antisocial behavior that onsets in early childhood and remains stable across the life-span. These men are responsible for 50% to 70% of all violent crimes (Moffitt, 1993; Hodgins, 1994). They fulfill diagnostic criteria for conduct disorder (CD) in childhood and antisocial personality disorder (ASPD) in adulthood. In Finland, for example, men with ASPD are responsible for approximately 60 to 80% of the most serious violent offenses (Tiihonen and Hakola, 1994; Eronen et al., 1996a). A recent survey indicated that about half of all prisoners in Western countries fulfill diagnostic criteria for ASPD that require by definition a diagnosis of CD prior to age 15 (Fazel and Danesh, 2002). Substance misuse is almost always co-morbid with CD and ASPD.

Within this population of males characterized by an early onset and a stable pattern of antisocial behavior that persists across the life-span, a subgroup presents the personality traits of psychopathy. As adults, this subgroup commits even more violent offences than the others (Hare and McPherson, 1984). Reliable and valid diagnoses can be made using the Psychopathy Checklist Revised (PCL-R; Schroeder et al., 1985; Hare, 1991; Fulero, 1995). Psychopathy is not included as a diagnosis in the ICD-10 or DSM-IV, even though it fits the definition of a personality disorder. It is more severe in its manifestation than ASPD in that it requires the presence of the two traits, Arrogant and Deceitful Interpersonal Behavior and Deficient Affective Experience, in addition to a history of antisocial behavior. A great deal of research has been conducted using the PCL-R as a dimension, and the total score has been consistently found to be the best known predictor of violent behavior (Hemphill et al., 1998).

Men with ASPD have been reported to show reductions in frontal grey matter volumes as compared with healthy men, and similar volumes of frontal white matter (Raine et al., 2000). However, one third of the individuals with ASPD in this study had also a schizophrenia spectrum disorder. Men with psychopathy have been described as having an abnormally structured corpus callosum (Raine et al., 2003). A recent review, however, has highlighted that few structural differences have been identified in this population and that none have been replicated (Pridmore

et al., 2005). In these studies, samples have been heterogeneous, inadequately characterized, poorly described, and not comparable. A recent study compared brain volumes, assessed with magnetic resonance imaging (MRI), of incarcerated offenders with personality disorders (75% of them diagnosed as psychopaths) and healthy men. No differences in frontal or temporal lobe volumes were observed. This study did not measure the grey or white matter separately (Dolan et al., 2002). We have previously compared offenders with ASPD and alcoholism and healthy men, and we observed no significant differences in prefrontal grey and white matter volumes (Laakso et al., 2002). To our knowledge, no other quantitative data have been reported on the neuroanatomy of persistent violent offenders with a history of antisocial behavior going back to at least mid-adolescence. It is not known if such men present abnormalities in brain structure. Given the paucity of replicated findings, we did not make hypotheses nor select specific regions for study. Rather, we used lobar analyses and voxel-based morphometry to compare the brain structures of persistent violent offenders who fulfill criteria for ASPD and healthy men in all brain regions. The sample of offenders was relatively homogeneous with respect to age of onset and history of antisocial behavior, persistence and severity of violent criminality, and absence of any history of severe mental illness.

2. Method

2.1. Participants

Healthy participants gave informed consent, and all data from offenders (MRI scans and case record files) were obtained retrospectively from hospital files. The procedure was approved by the ethical committee of Kuopio University Hospital. All participants were of Finnish origin. The healthy comparison group included 25 men – students, hospital staff and skilled workers – who were considered to be free of current or past substance misuse and other mental disorders on the basis of unstructured interview. Intelligence quotient (IQ) scores were not available from the comparison subjects. The offender group included 26 men with no history or current diagnosis of psychosis or schizotypal personality disorder who were consecutively admitted to a university forensic psychiatric

Table 1
Comparison of sociodemographic and clinical characteristics (mean ± S.D.) of the healthy men and the violent offenders

	Healthy men (N=25)	Violent offenders (N=26)	Statistic	P-value
Age, years	34.6 ± 10.8	32.5 ± 8.4	$t=0.783$	0.438
Ethnicity, % white	100%	100%	Fisher exact test	1.000
Alcohol dependence, %	0	100%	Fisher exact test	<0.001
Polysubstance abuse, %	0	76.9%	Fisher exact test	<0.001
Total intracranial volume	1707 ± 117	1654 ± 108	$t=1.664$	0.102

hospital for a pre-trial assessment. All were charged with violent offences (2 murder, 10 manslaughter, 4 attempted murder or manslaughter, 1 assisting manslaughter, 6 assaults, 3 armed robberies). All had a history of recurrent violent acts, and all but two had previous convictions for violence. Data on handedness were not available. The characteristics of the participants are presented in Table 1. One of the offenders had a history of head injury leading to transient unconsciousness. None of the offenders had a diagnosis of mental disorder or behavioral disorder caused by previous brain damage.

Diagnoses were made by consensus using multiple sources of information including reports from multidisciplinary treatment teams, family members, colleagues from work, and medical and criminal files. All offenders fulfilled criteria for both DSM-IV ASPD and ICD-10 dissocial personality, and none fulfilled criteria for schizotypal personality disorder or any current or past psychotic disorder. All met the criterion for a maladaptive pattern of substance abuse related to alcohol abuse (DSM-IV, APA 1994) with early onset corresponding type 2 as described by Cloninger (Cloninger, 1987), and all fulfilled the DSM-IV and ICD 10 criteria for substance dependence with 20 fulfilling criteria for drug polysubstance dependence and 6 for alcohol dependence. Fifteen offenders had used amphetamine at least once (9 from the high psychopathy group and 6 from the low psychopathy group). Participants had no access to alcohol for 3 to 6 months prior to the brain scan and no access to illicit drugs for 1 to 7 weeks prior to the brain scan. (The different abstinence periods are explained by the fact that while storage and use of intoxicating amounts of alcohol by prisoners are difficult and rare in Finnish prisons, the delivery and use of illicit drugs is much easier and rather common.) Eleven of the offenders were free of psychotropic medication, and 15 were taking either benzodiazepine, antidepressant or

antipsychotic medication (small doses used as anxiolytic or hypnotic).

2.2. Psychopathy ratings

The PCL-R was used to assess psychopathy (Hare, 1991). For detailed information, see <http://www.niuvu.fi/tuttex.html>.

2.3. Magnetic resonance imaging

Comparisons between study groups were done by using voxel-based morphometry (VBM) and lobar volumetry. Lobar analyses provide quantitative information on brain volume alterations in large regions of interest. VBM addressed the significance of volume alterations in much more restricted areas that can be as small as a single voxel. The participants were scanned with a 1.0 T Impact (Siemens; Erlangen, Germany) using a standard head coil and a tilted T1-weighted coronal 3D gradient echo sequence (magnetization prepared rapid acquisition gradient echo: TR 10 ms, TE 4 ms, TI 250 ms, flip angle 12°, FOV 250 mm, matrix 256 × 192, 1 acquisition). The 3-D spatial resolution was 2.0 mm × 1.3 mm × 0.97 mm.

MR images were processed with SPM2 (<http://www.fil.ion.ucl.ac.uk/spm/software/spm2>) following an optimized protocol including: (a) generation of a whole brain customised template, (b) generation of customised prior probability maps, and (c) main VBM steps to applied on original images. For detailed information, see Supplementary Material, doi:10.1016/j.psychresns.2007.08.012.

2.4. Statistical analyses

In the analyses, the healthy men were compared with the 26 violent offenders with ASPD and to the subgroup of 12 offenders who fulfilled criteria for a diagnosis of psychopathy. Student's t -test, chi-square test and Fisher exact test were used to compare participants' sociodemographic and clinical characteristics. Analysis of covariance (ANCOVA) was used to evaluate the age-adjusted differences between the violent offenders and healthy men in the lobar volumetry analysis. Effect size (Cohen's d) was used to describe the robustness of the findings (Cohen, 1988). Within the offender group, univariate analysis of variance (full factorial model) was used to assess the contribution of variables such as PCL-R scores, IQ scores, duration of alcohol abuse, polysubstance abuse and use of current psychotropic medication to regional brain volumes. The association between PCL-R factor scores and regional brain volumes was assessed using Pearson's correlation analysis. In VBM, grey matter and white matter images

Table 2

Comparisons of sociodemographic and clinical characteristics (mean±S.D.) of the offenders with psychopathy and those with only ASPD

	Offenders with psychopathy (N=12)	Offenders with only ASPD (N=14)	Statistic	P-value
Mean age (in years)	33.0±8.6	32.1±8.5	$t=0.256$	0.800
Duration of alcohol abuse (in years)	19.6±10.0	18.3±8.9	$t=0.356$	0.725
Polysubstance abuse	100%	57%	$\chi^2=6.69$	0.010
Mean global IQ score	94.7±8.6	88.7±8.8	$t=1.740$	0.095
Current psychotropic medication	67%	50%	$\chi^2=0.74$	0.391
Mean score PCL-R total	34.6±3.1	25.9±2.8	$t=7.566$	<0.001
Mean score for Arrogant and deceitful interpersonal style	6.03±1.74	1.90±1.12	$t=7.287$	<0.001
Mean score for Deficient affective experience	7.83±0.58	6.14±1.10	$t=4.782$	<0.001
Mean score for Impulsive, irresponsible behavioral style	9.67±1.15	9.71±0.47	$t=-0.142$	0.889

The IQ of the offenders was assessed using the Wechsler Adult Intelligence Scale — revised (Wechsler, 1981).

were analyzed with an ANCOVA model (see Supplementary Material, MRI method paragraph for details, doi:10.1016/j.psychresns.2007.08.012).

3. Results

Comparisons of the sociodemographic and clinical characteristics of the violent offenders and healthy men are shown in Table 1. As can be seen, no differences were observed between the violent offenders and healthy men as to age, ethnicity and intracranial volume. More of the violent offenders than the healthy men had a history of alcohol and polysubstance abuse. As presented in Table 2, the subgroup of offenders with psychopathy was similar to the other offenders with only ASPD as to age, duration of alcohol abuse, global IQ score, and the proportion taking medication. All of the offenders with psychopathy had a history of polysubstance misuse as compared with 57% of the other offenders. By definition, the offenders with psychopathy obtained higher total PCL-R scores, and also higher scores for the two factors assessing the personality traits of psychopathy, Arrogant and Deceitful Interpersonal Behavior and Deficient Affective Experience.

3.1. Regional brain volumes

The adjusted lobar regional brain volumes of offenders as compared with the healthy men are shown in Table 3. Regional volumes correlated strongly with each other (Pearson r up to 0.99), and 85% (161 of 190) of the correlations were statistically significant ($P<0.05$). Offenders displayed greater volumes in most areas than the healthy men, and the age-adjusted differences were statistically significant without Bonferroni corrections in the right cerebellar grey matter, left cerebellar white matter, and parietal and occipital white matter bilaterally. The violent offenders had much more occipital white matter than the healthy men, with effect sizes reaching 1.15 on the right and 1.24 on the left. These comparisons remained statistically significant after applying Bonferroni corrections for multiple comparisons. When the subgroup of violent offenders diagnosed as psychopaths were compared with the healthy men, the effect sizes were slightly larger than those observed in comparisons between all the offenders and the healthy men (0.69 for right cerebellar grey matter, $P=0.064$; 0.63 for left cerebellar white matter, $P=0.075$; 0.77 for right parietal white matter, $P=0.04$; 0.84 for left parietal white matter, $P=0.026$; 1.30 for right occipital white matter, $P=0.001$; and 1.51 for left occipital white matter, $P<0.001$). Since amphetamine use *per se* has been suspected to affect regional brain volumes (Thompson et al., 2004; Jernigan et al., 2005), we made separate analyses among amphetamine-naïve subjects. Those offenders who had never used amphetamine ($n=11$, 3 belonging to high psychopathy group and 8 to the low psychopathy group) displayed greater volumes in all 6 areas than the healthy men, and this difference was statistically significant in right occipital white matter (effect size 0.78, $P=0.033$) and left occipital white matter (effect size 1.03, $P=0.009$).

We further examined the six brain regions (right cerebellar grey matter, left cerebellar white matter, and parietal and occipital white matter bilaterally) where the offenders displayed greater volumes than the healthy men. Among the 26 violent offenders, associations between the adjusted volumes in these regions and total PCL-R total scores, global IQ scores, duration of alcohol abuse, presence of polysubstance abuse, and use of current psychotropic medication were not statistically significant. The only significant correlation between the adjusted brain volumes in these regions and PCL-R factor scores was observed between the score for Impulsive Irresponsible Lifestyle and left cerebellar white matter ($r=-0.52$, $P=0.006$; Bonferroni corrected significance level $P=0.05/6=0.008$). Correlations between regional brain volumes and scores for Arrogant and Deceitful Behavior

Table 3

Adjusted (native brain volume/total intracranial volume×1000) brain volumes (mean±S.D.) in healthy men and violent offenders

		Healthy men (N=25)	Violent offenders (N=26)	Effect size ^a	Age-adjusted ANCOVA	
					<i>F</i> _{1,48}	<i>P</i> ^b
<i>Grey matter</i>						
Frontal	Right	146.1±14.1	148.1±20.2	0.11	0.001	0.971
	Left	148.3±15.0	149.0±20.0	0.04	0.150	0.700
Temporal	Right	46.7±3.7	44.8±5.0	0.24	0.359	0.552
	Left	46.4±3.9	47.7±5.2	0.28	0.555	0.460
Parietal	Right	74.7±6.6	74.7±9.2	0.01	0.173	0.679
	Left	76.4±6.7	75.9±9.2	−0.05	0.450	0.505
Occipital	Right	58.2±5.0	57.6±7.7	−0.08	0.353	0.555
	Left	55.8±5.0	55.8±6.1	0.01	0.085	0.771
Cerebellar	Right	63.7±4.7	67.2±5.9	0.67	4.993	0.030
	Left	64.2±4.0	67.0±5.7	0.57	3.548	0.066
<i>White matter</i>						
Frontal	Right	159.1±13.3	163.9±12.8	0.37	1.693	0.199
	Left	163.3±11.6	167.5±13.1	0.35	1.585	0.214
Temporal	Right	17.1±2.5	16.89±3.2	−0.08	0.015	0.903
	Left	20.2±2.5	20.3±3.4	0.02	0.072	0.789
Parietal	Right	74.4±5.9	78.9±5.9	0.76	6.936	0.011
	Left	74.4±5.4	78.6±5.5	0.76	6.905	0.012
Occipital	Right	46.2±4.0	51.2±4.7	1.15	15.779	<0.001
	Left	42.8±3.4	47.7±4.4	1.24	18.727	<0.001
Cerebellar	Right	16.5±1.6	17.1±1.6	0.04	2.070	0.157
	Left	16.6±2.2	17.8±1.7	0.63	4.984	0.030

^a Effect size is Cohen's *d* (Cohen, 1988).^b When Bonferroni correction for multiple comparisons is applied, the level of significance is *P*=0.0025.

were modest and positive (ranging from 0.12 to 0.25), and those between brain volumes and Deficient Affective Experience were modest and negative (ranging from −0.07 to −0.31). No statistically significant correlations were observed in the regional volumes vs. PCL-R scores in the other 14 brain regions.

Volumes of cerebrospinal fluid (CSF) were similar among offenders and healthy men, except in the left frontal region where offenders displayed larger volumes (*F*=5.68, *P*=0.021, age-adjusted ANCOVA).

3.2. Voxel-Based Morphometry

The results of comparisons of the 26 violent offenders and 25 healthy men on voxel-based morphometry of the grey matter are presented in Table 4. The violent offenders were characterized by focal, and strikingly symmetrical areas of atrophy in the postcentral gyri, frontopolar cortex (superior and medial frontal gyrus), and orbitofrontal cortex as shown in Fig. 1. In addition, substantially smaller volumes were observed in the left posterior cingulate cortex and the right insula. In comparisons of the 12 offenders with psychopathy and the healthy men, the differences in these same areas remained significant

(*P*<0.05 corrected), and the *z*-scores were slightly larger than those obtained for the comparisons between all offenders and the healthy men. A *z*-score of 5.59 was obtained for the difference between the offenders with psychopathy and the healthy men for left inferior parietal lobule, 4.34 for right parietal lobule, 4.25 for left frontopolar cortex, and 4.19 for right frontopolar cortex (*P*<0.05 corrected for false discovery rate). In the comparison between the offenders with psychopathy and the healthy men, markedly smaller densities were also observed in the left middle temporal gyrus (cluster size 1336 mm³, *x*=−38, *y*=−78, *z*=20, *z*-score 4.06), and left parahippocampal gyrus (cluster size 3640 mm³, *x*=−30, *y*=−58, *z*=−8, *z*-score 3.99). In comparisons of the 14 offenders with ASPD only compared with the healthy men or compared with offenders with psychopathy, no significant volume reductions were observed.

Areas of smaller grey matter volume in offenders who never used amphetamine (*N*=11) compared with controls (*N*=25) measured with voxel-based morphometry (*P*<0.001 uncorrected) were observed in the left orbital prefrontal cortex (cluster size 792 mm³, *x*=−20, *y*=42, *z*=−22, *z*-score=4.27), in the left occipital gyrus (cluster size 1200 mm³, *x*=−18, *y*=−58, *z*=10,

Table 4

Areas of smaller grey matter volume in violent offenders ($N=26$) compared with healthy men ($N=25$) measured with voxel-based morphometry (corrected for false discovery rate at $P<0.05$)

Cluster size mm ³	Regions	Stereotactic coordinates (mm)			Z score
		x	y	z	
13032	L Inferior Parietal Lobule	-52	-34	36	5.06
	L Inferior Parietal Lobule	-40	-42	46	4.50
	L Postcentral Gyrus	-44	-22	48	4.13
6576	R Inferior Parietal Lobule	44	-32	48	4.80
	R Postcentral Gyrus	30	-44	58	3.53
21384	L Posterior Cingulate	-18	-60	12	4.74
	L Precuneus	-14	-64	18	4.45
	L Precuneus	-10	-68	24	4.40
5960	L Superior Frontal Gyrus	-20	42	-22	4.73
	L Superior Frontal Gyrus	-22	60	12	3.94
	L Superior Frontal Gyrus	-14	64	20	2.97
6360	L Paracentral Lobule	-8	-28	46	3.98
	L Precuneus	-6	-52	40	3.47
	L Medial Frontal Gyrus	-2	-8	52	3.32
352	R Superior Frontal Gyrus	20	42	-20	3.97
2816	L Inferior Frontal Gyrus	-36	22	4	3.86
4488	R Medial Frontal Gyrus	12	64	6	3.86
	R Middle Frontal Gyrus	24	60	6	3.85
	R Superior Frontal Gyrus	28	56	14	3.68
1416	Fusiform Gyrus	56	-24	-30	3.73
3088	R Insula	32	22	8	3.59
	R Caudate	12	14	-4	3.25
848	L Superior Temporal Gyrus	-48	-60	28	3.50
416	L Middle Temporal Gyrus	-52	-56	0	3.43
1504	Lentiform Nucleus	-18	18	0	3.39
736	L Middle Temporal Gyrus	-38	-78	20	3.34
648	L Middle Frontal Gyrus	-30	-8	62	3.28
	L Middle Frontal Gyrus	-40	0	60	2.93
808	L Fusiform Gyrus	-48	-32	-18	3.26
	L Fusiform Gyrus, Grey	-58	-24	-26	3.09
	L Fusiform Gyrus	-50	-26	-24	3.06

Only those clusters larger than 250 mm³ are shown.

L = left, R = right.

Reading example: the most significant voxel of the cluster has stereotactic coordinates of -52, -34, 36 and is located in the region of left Inferior Parietal Lobule. Within the same cluster there are two more peak of significance distant more than 8 mm from the former and located at -40, -42, 46 and at -44, -22, 48.

z -score=3.80), in the right postcentral gyrus (cluster size 920 mm³, $x=46$, $y=-30$, $z=46$, z -score=3.75), in the left postcentral gyrus (cluster size 312 mm³, $x=-52$, $y=-36$, $z=36$, z -score=3.65), in the right superior frontal gyrus (cluster size 392 mm³, $x=28$, $y=54$, $z=16$, z -score=3.59), and in the right inferior temporal cortex (cluster size 416 mm³, $x=58$, $y=-22$, $z=-30$, z -score=3.46). However, due to the low number of subjects in these subgroups, none of these comparisons survived FDR-correction. No areas of decreased grey matter were observed in the opposite comparison.

Table 5 and Fig. 2 present the results of voxel-based morphometry of white matter. Violent offenders were characterized by areas of increased white matter density in widespread regions, whereas decreased density of white matter was observed only in one location in right medial frontal gyrus when compared with healthy men. Areas of larger white matter volume in subjects with high psychopathy ($N=12$) compared with subjects with low psychopathy ($N=14$) measured with voxel-based morphometry ($P<0.001$ uncorrected) were observed in the right angular gyrus (cluster size 752 mm³, $x=48$, $y=-30$, $z=46$, z -score=3.99), in the right inferior temporal gyrus (cluster size 416 mm³, $x=48$, $y=-22$, $z=-24$, z -score=3.70) and in the left cerebellum (cluster size 632 mm³, $x=-14$, $y=-56$, $z=-44$, z -score=3.69). However, due to the low number of subjects in these subgroups, none of these comparisons survived FDR-correction. No areas of decreased white matter were observed in the opposite comparison.

4. Discussion

To our knowledge, this study reports the first evidence that persistent violent offenders who fulfill the diagnostic criteria for ASPD are characterized by abnormal brain anatomy when compared with healthy men. Despite the fact that all 26 violent offenders had a history of substance dependence, lobar volumetry indicated that they had markedly larger grey matter volume in the right cerebellum and larger white matter volume in the right and left parietal lobes, right and left occipital lobes, and left cerebellum. The differences in these regions were even greater in comparisons of the offenders with psychopathy and healthy men. Voxel-based morphometry revealed that the violent offenders displayed symmetrical, bilateral areas of grey matter atrophy in the postcentral gyri, frontopolar cortex and orbitofrontal cortex and unilateral volume loss in the left posterior cingulate cortex and right insula as compared with the healthy men. These reductions in volume were even greater among the subgroup of offenders with a diagnosis of psychopathy.

The results of the present study concur with findings from two structural MRI investigations of adolescent boys with CD. In the present study, the violent offenders displayed distinct areas of reduced temporal gray matter compared with the healthy men consistent with the findings of Kruesi et al. (2004) of bilateral reductions in temporal grey matter among boys with CD. Consistent with Sterzer et al. (2005a), a significant reduction in volume of the insula was evident among

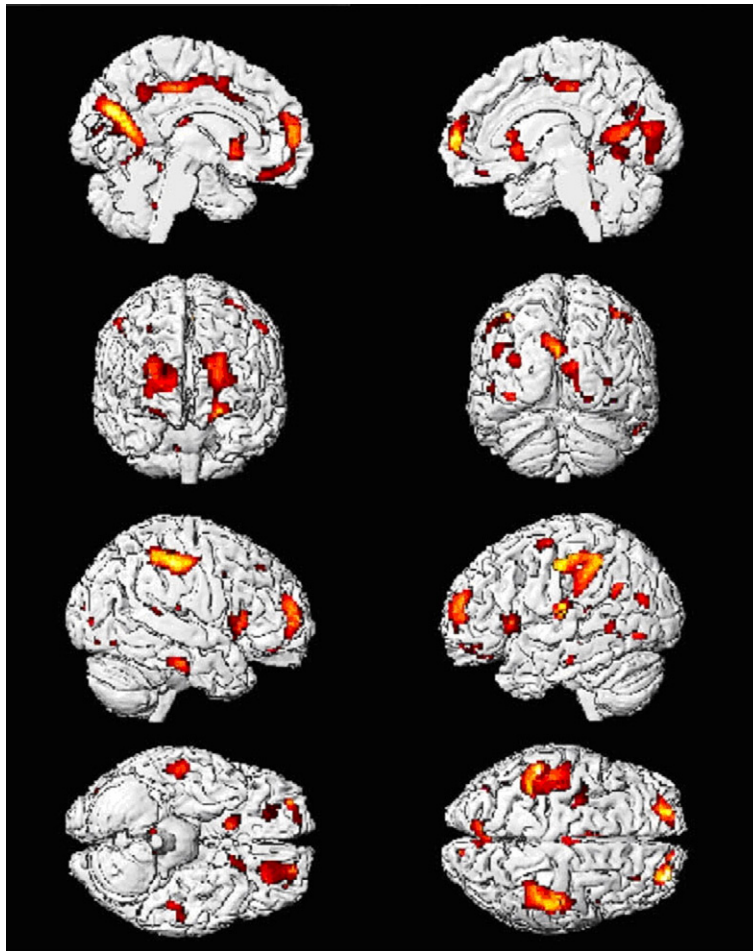


Fig. 1. Gray matter volume loss in subjects with antisocial personality disorder ($N=26$) compared with comparison subjects ($N=25$) (corrected for false discovery rate at $P<0.05$). Note the striking symmetry of smaller gray matter volumes in postcentral gyri, frontopolar cortex, and orbitofrontal cortex.

the persistent violent offenders as compared with the healthy men in the present study. In contrast to [Sterzer et al. \(2005b\)](#) and to much theorizing about the primary role that the amygdala may play in the development of psychopathy ([Blair, 2005](#)), no differences were detected in the volumes of the amygdala between the violent offenders and healthy men. We have previously observed negative correlations between the volumes of the hippocampus ([Laakso et al., 2001](#)) and the amygdala ([Tiihonen et al., 2000](#)) and total PCL-R scores among different sample of offenders. The offenders in the present study did, however, show reduced volume of the parahippocampal gyrus as compared with the healthy men.

Our findings are in line with results of a recent functional MRI study, which observed less activation in the limbic circuit (parahippocampal gyrus, orbitofrontal cortex, insula, and anterior and posterior cingulate) during

acquisition of fear among men with psychopathy as compared with healthy men ([Birbaumer et al., 2005](#)). Frontal cortex and, especially, orbitofrontal cortex are key areas in the regulation of violent and aggressive behavior ([Grafman et al., 1996](#); [Birbaumer et al., 2005](#)). The finding of reduced grey matter volumes in these areas adds further support to hypotheses that the orbitofrontal cortex is malfunctioning among persistently violent offenders with a history of early-onset stable antisocial behavior ([Anderson et al., 1999](#)). Further, the findings concur with evidence showing that offenders with psychopathy present difficulties in neuropsychological tasks thought to be dependent on the integrity of the orbitofrontal cortex ([Lapierre et al., 1995](#); [Blair, 2004](#)).

The increased white matter observed among the persistent violent offenders, as compared with the healthy men, was not due to the size of the corpus callosum (as can be seen in [Fig. 2](#)). This result does not concur with a

Table 5

Areas of larger white matter volume in violent offenders ($N=26$) compared with healthy comparison subjects ($N=25$) measured with voxel-based morphometry ($P<0.001$ uncorrected)

Cluster size mm ³	Regions	Stereotactic coordinates (mm)			Z score
		x	y	z	
784	R supramarginal gyrus	56	-36	38	4.62
928	L superior frontal gyrus	-10	62	2	4.10
	L superior frontal gyrus	-16	62	18	3.58
	L superior frontal gyrus	-20	64	4	3.23
360	R superior frontal gyrus	22	64	8	4.09
288	R occipital lobe	42	-78	20	3.90
272	R occipital lobe	48	-62	30	3.87
	R occipital lobe	42	-70	40	3.20
416	R occipital lobe	42	-82	-8	3.81
928	R occipital lobe	32	-58	-8	3.64
	R fusiform gyrus	34	-48	-12	3.28
936	R internal capsule	18	20	0	3.60

When FDR-correction was applied, only the cluster in the right supramarginal gyrus (z -score 4.62) remained statistically significant ($P<0.05$ FDR corrected). No areas of decreased white matter were observed in the opposite comparison.

previous finding of larger corpus callosum among men with psychopathy (Raine et al., 2003). The participants in this latter study, unlike the offenders in the present study, were not characterized by persistent violent offending and some had diagnoses of schizophrenia spectrum disorders. Further, Raine and colleagues (2003) did not examine any other areas of white matter except the corpus callosum, and they used region of interest volumetry, while we used voxel-based morphometry.

The violent offenders in the present study were characterized by long histories of substance abuse and all 26 met criteria for either polysubstance drug dependence ($n=20$) or alcohol dependence ($n=6$). Substance abuse is associated with decreased grey and white matter volume (Aasly et al., 1993; Liu et al., 1998; Agartz et al., 2003; Lyoo et al., 2006), and although these volume reductions reverse to some extent during abstinence, brain volumes do not normalize to the level of healthy individuals (Agartz et al., 2003). Our results on grey matter volume loss in the occipital lobe, posterior cingulate and medial frontal cortex are strikingly similar to those reported by Thompson et al. (2004) among methamphetamine users. Our results showed that this kind of grey matter volume loss was observed also among those offenders who had never used amphetamine, which suggests that observed focal GM volume decreases may be associated more with personality traits or other factors which lead to amphetamine abuse than with neurotoxic effects of amphetamine. It has been observed that methamphetamine use may be associated with larger

temporal and occipital white matter volume (Thompson et al., 2004) and parietal grey matter volume (Jernigan et al., 2005). Chronic methamphetamine use has been observed to induce inflammation and glial proliferation (Escubedo et al., 1998) which may contribute to white matter volume increase. Our analysis on the subgroup of offenders who had never used amphetamine revealed that these offenders also had substantially larger volumes in posterior brain areas than the healthy men, which indicates that our findings are not entirely attributable to amphetamine use *per se*, but are associated with factors that place the individual at higher risk for amphetamine use. We hypothesize that the larger regional volumes observed in posterior brain areas reflect atypical neurodevelopmental processes which may underlie the development of early-onset and stable antisocial behavior. Substance abuse has been shown to disrupt the development of the cerebellum (Hauser et al., 2003). Males who display CD in childhood are known to be exposed earlier than other children to alcohol and drugs (Armstrong and Costello, 2002). It is reasonable to speculate that the violent offenders in the present study, all of whom fulfilled criteria for ASPD, CD and substance dependence, may have used large doses of alcohol and drugs at a young age leading to an interruption of synaptic elimination (or pruning) that occurs during adolescence (Blakemore and Choudhury, 2006). We speculate that the larger volumes of white matter that were observed in several brain regions among the violent offenders may be the result of environmentally or genetically triggered disruption of brain maturation. Boys with CD not only begin using alcohol and drugs at a young age, but in childhood, they experience higher rates of accidents and infections than other boys (Aarons et al., 2003), and the consequences of persistent physical fighting. In addition to these possible environmental factors that could disrupt brain maturation, a disruption could also result from genetic programming.

Polysubstance abuse is associated with diffuse grey matter loss (Aasly et al., 1993; Liu et al., 1998; Lyoo et al., 2006). Therefore, it is possible that even the focal reductions in grey matter volumes that we observed among the violent offenders may be attributable, at least in part, to substance abuse. However, it is remarkable that the lobar analysis indicated that the offenders displayed slightly larger grey matter volumes than the healthy men in most areas. It is highly unlikely that this finding could be explained by substance abuse. The offenders also had significantly greater CSF volumes in the left frontal lobe, which may be an indicator of a slight substance abuse-induced atrophy in this area.

It has been observed that brain volumes correlate positively with IQ (Haier et al., 2004). IQ test scores

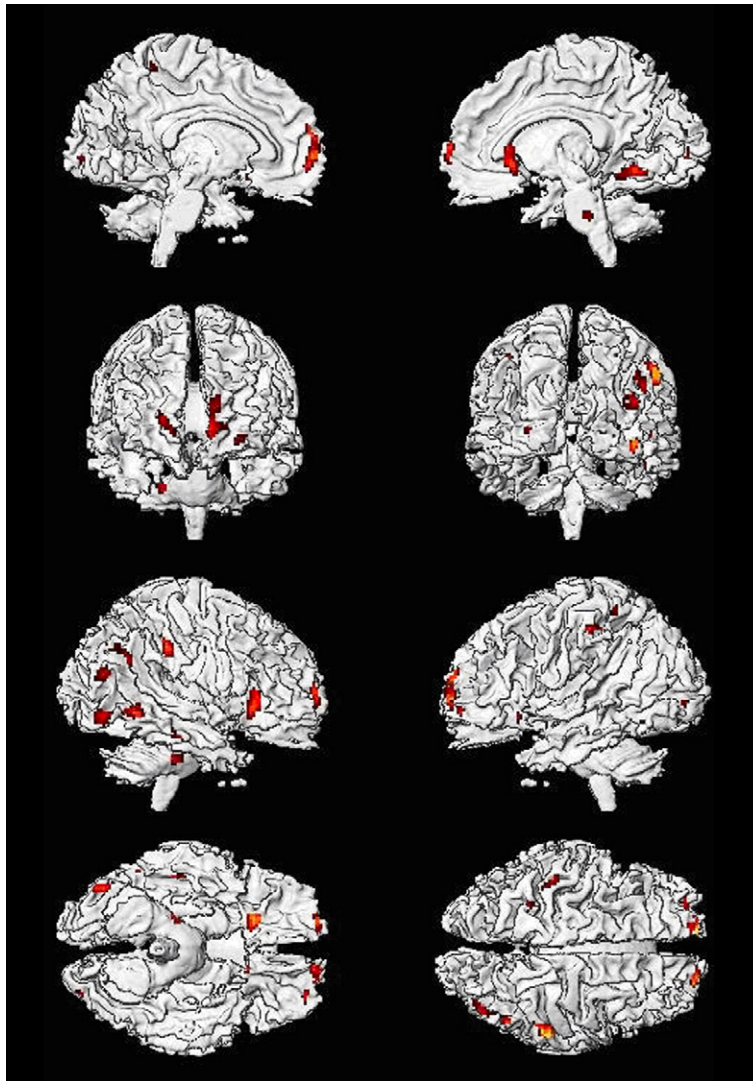


Fig. 2. Brain areas where violent offenders had larger white matter volumes than controls ($P < 0.001$, uncorrected).

were not available for the healthy men and consequently analyses could not be adjusted for this important covariate. However, the reductions in regional brain volumes observed among the offenders are not likely attributable to lower IQ. The greatest differences in regional brain volumes were observed in comparisons between the subgroup of offenders with a diagnosis of psychopathy and the healthy men. Consistent with previous studies (Hicks et al., 2004), the offenders with psychopathy obtained IQ scores that were, on average, 6 points higher than those obtained by the other offenders who fulfilled diagnostic criteria for ASPD. Although no statistically significant linear correlations were observed between PCL-R scores and regional brain volumes, we cannot rule out a non-linear correlation, since all offenders had relatively high PCL-R scores (≥ 21 ,

range 21–40). The observed negative correlation between Impulsive Irresponsible Lifestyle vs. left cerebellar white matter volume may be explained by heavier substance abuse (leading to slight atrophy among those offenders with high scores of Impulsive Irresponsible Lifestyle).

We observed no trend towards smaller total frontal lobe grey matter density among the persistently violent offenders as compared with the healthy men. This differs from previous reports of reduced frontal grey matter among men with ASPD (Raine et al., 2000) and among men labelled “unsuccessful psychopaths” (Yang et al., 2005). But, the participants in these previous studies were not characterized by persistent violent offending and one third of those with ASPD were also diagnosed with schizophrenia spectrum disorders.

The volume loss in postcentral gyri that we observed among the persistently violent offenders may be associated with their inability to recognize or anticipate the emotions of other people (Hare, 1998; Blair, 2003). This somatosensory area receives projections from the face and contributes to the mirror neuron system that is involved in experiencing empathy, expression of emotions, and social co-operation (Kohler et al., 2002). Volume reductions in frontopolar, orbitofrontal and parietal cortex, as well as insula and posterior cingulate cortex, may be determinants of psychopathy, since these regions are implicated in processing the experience of empathy and theory of mind (Farrow et al., 2001; Moll et al., 2001; Vollm et al., 2006) and in decision making and risk taking (Paulus et al., 2003).

A large number of brain regions have been proposed as possible determinants of early-onset persistent antisocial behavior. We reasoned that the evidence, however, was not sufficient to select any of these areas for study. Rather, we conducted whole brain analysis using voxel-based morphometry. The advantage of this approach is that no region-specific hypotheses are required, but the disadvantage is that, because of conservative statistics, differences of medium magnitude in small structures such as the amygdala may fail to reach statistical significance, resulting in a type 2 error. On the other hand, small local alterations may remain undetected in the lobar analysis which indicates the total volume of a relatively large brain area. In the lobar analysis, the use of the Bonferroni formula to correct the level of significance in order to avoid type 1 errors is also problematic since this formula should be used to correct for multiple comparisons that are independent from each other. This principle implies that it should not be used in the present study where lobar volumes were strongly correlated with each other. The differences, however, in the occipital white matter between the offenders and healthy men were very robust and would have survived even a vigorous Bonferroni correction.

The sample of persistent violent offenders that was studied was representative of violent offenders in Finland who show an early-onset pattern of antisocial behavior that is stable across the life-span. In Finland, approximately 70% of persons accused of a serious violent offense are required to undergo a pre-trial assessment in an inpatient unit of a forensic hospital (Eronen et al., 1996b) and it was from this population that we obtained our sample. Generally, the results of the present study concur with studies of adolescent boys with CD and adult offenders with a diagnosis of psychopathy, most of whom would be persistent violent offenders (Hare, 1991). Notably, in the present study the

differences between the violent offenders and healthy men were even stronger for the subgroup with than without a diagnosis of psychopathy. The results of the present study do not concur with previous findings from men with ASPD who were not persistent violent offenders. This observation could be important for defining samples for future studies and underlines the necessity of precisely characterizing study samples.

In conclusion, the results of the present study indicate that persistent violent offenders with ASPD present markedly abnormal white and grey matter regional brain volumes as compared with healthy men. Substantially larger regional volumes in the posterior brain areas were observed among violent offenders with a history of antisocial behavior going back to childhood. These marked differences in brain structure may reflect atypical neurodevelopmental processes that are involved in the initiation and maintenance of persistent aggressive behavior.

Acknowledgements

This study was supported by the Research Council for Health of the Academy of Finland, an EVO grant from the Kuopio University Hospital, the Sigrid Jusélius Foundation and by the Ministry of Health and Social Affairs of Finland. S. Hodgins is a Royal Society Wolfson Merit Award Holder. RR, CT, JP and GBF were supported by the Italian Ministry of Health.

The authors thank Ms. Aija Räsänen for secretarial assistance.

Appendix A. Supplementary data

Supplementary data associated with this article can be found, in the online version, at [doi:10.1016/j.pscychresns.2007.08.012](https://doi.org/10.1016/j.pscychresns.2007.08.012).

References

- Aarons, G.A., Ziegenhorn, L.A., Brown, S.A., 2003. Adolescent conduct disorder, substance use, and traumatic injury. *Journal of Child & Adolescent Substance Abuse* 12, 1–18.
- Aasly, J., Storsaeter, O., Nilsen, G., Smevik, O., Rinck, P., 1993. Minor structural brain changes in young drug abusers. A magnetic resonance study. *Acta Neurologica Scandinavica* 87, 210–214.
- Agartz, I., Brag, S., Franck, J., Hammarberg, A., Okugawa, G., Svinhufvud, K., Bergman, H., 2003. MR volumetry during acute alcohol withdrawal and abstinence: a descriptive study. *Alcohol* 38, 71–78.
- American Psychiatric Association, 1994. *Diagnostic and Statistical Manual of Mental Disorders*, fourth edition. The Association, Washington, DC.
- Anderson, S.W., Bechara, A., Damasio, H., Tranel, D., Damasio, A.R., 1999. Impairment of social and moral behavior related to early

- damage in human prefrontal cortex. *Nature Neuroscience* 2, 1032–1037.
- Armstrong, T., Costello, E.J., 2002. Community studies on adolescent substance use, abuse, or dependence and psychiatric comorbidity. *Journal of Consulting and Clinical Psychology* 70, 1224–1239.
- Birbaumer, N., Veit, R., Lotze, M., Erb, M., Hermann, C., Grodd, W., Flor, H., 2005. Deficient fear conditioning in psychopathy: a functional magnetic resonance imaging study. *Archives of General Psychiatry* 62, 799–805.
- Blair, R.J.R., 2003. Neurobiological basis of psychopath. *British Journal of Psychiatry* 182, 5–7.
- Blair, R.J.R., 2004. The roles of orbital frontal cortex in the modulation of antisocial behavior. *Brain Cognition* 55, 198–208.
- Blair, R.J.R., 2005. Applying a cognitive neuroscience perspective to the disorder of psychopathy. *Development and Psychopathology* 17, 867–891.
- Blakemore, S.J., Choudhury, S., 2006. Development of the adolescent brain: implications for executive function and social cognition. *Journal of Child Psychology and Psychiatry* 47, 296–312.
- Cloninger, C.R., 1987. A systematic method for clinical description and classification of personality variants: a proposal. *Archives of General Psychiatry* 44, 573–588.
- Cohen, J., 1988. *Statistical Analysis for the Behavioral Sciences*, 2nd ed. Lawrence Erlbaum Associates, Hillsdale, NJ.
- Dolan, M., Deakin, W.J., Roberts, N., Anderson, I., 2002. Serotonergic and cognitive impairment in impulsive aggressive personality disordered offenders: are there implications for treatment? *Psychological Medicine* 32, 105–117.
- Eronen, M., Hakola, P., Tiihonen, J., 1996a. Factors associated with homicide recidivism in a 13-year sample of homicide offenders in Finland. *Psychiatric Services* 47, 403–406.
- Eronen, M., Hakola, P., Tiihonen, J., 1996b. Mental disorders and homicidal behavior in Finland. *Archives of General Psychiatry* 53, 497–501.
- Escubedo, E., Guitart, L., Sureda, F.X., Jimenez, A., Pubill, D., Pallas, M., Camins, A., Camarasa, J., 1998. Microgliosis and down-regulation of adenosine transporter induced by methamphetamine in rats. *Brain Research* 814, 120–126.
- Farrow, T.F., Zeng, Y., Wilkinson, I.D., Spence, S.A., Deaking, J.F., Tarrier, N., Griffiths, P.D., Woodruff, P.W., 2001. Investigating the functional anatomy of empathy and forgiveness. *Neuroreport* 12, 2433–2438.
- Fazel, S., Danesh, J., 2002. Serious mental disorder in 23000 prisoners: a systematic review of 62 surveys. *Lancet* 359, 545–550.
- Fulero, S.M., 1995. Review of the Hare Psychopathy Checklist — revised. In: Concoley, J.C., Impara, J. (Eds.), *Twelve Mental Measurements Yearbook*. Buros Institute, Lincoln, NE, pp. 453–454.
- Grafman, J., Schwab, K., Warden, D., Pridgen, A., Brown, H.R., Salazar, A.M., 1996. Frontal lobe injuries, violence, and aggression: a report of the Vietnam Head Injury Study. *Neurology* 46, 1231–1238.
- Hare, R.D., McPherson, L.M., 1984. Violent and aggressive behavior by criminal psychopaths. *International Journal of Law and Psychiatry* 7, 35–50.
- Hare, R.D., 1991. *The Hare Psychopathy Checklist — Revised*. Multi-Health Systems, Toronto.
- Hare, R.D., 1998. Psychopathy, affect and behavior. In: Cooke, D.J., Forth, A.E., Hare, R.D. (Eds.), *Psychopathy: Theory, Research and Implications for Society*. Kluwer, Dordrecht, The Netherlands, pp. 105–138.
- Hauser, K.F., Khurdayan, V.K., Goody, R.J., Nath, A., Saria, A., Pauly, J.R., 2003. Selective vulnerability of cerebellar granule neuroblasts and their progeny to drugs with abuse liability. *Cerebellum* 2, 184–195.
- Haier, R.J., Jung, R.E., Yeo, R.A., Head, K., Alkire, M.T., 2004. Structural brain variation and general intelligence. *Neuroimage* 23, 425–433.
- Hemphill, J.R., Hare, R.D., Wong, S., 1998. Psychopathy and recidivism: a review. *Legal and Criminological Psychology* 3, 139–170.
- Hicks, B.M., Patrick, C.J., Markon, K.E., Krueger, R.F., Newman, J.P., 2004. Identifying psychopathy subtypes on the basis of personality structure. *Psychological Assessment* 16, 276–288.
- Hodgins, S., 1994. Status at age 30 of children with conduct problems. *Studies on Crime and Crime Prevention* 3, 41–62.
- Jernigan, T.L., Gamst, A.C., Archibald, S.L., Fennema-Notestine, C., Mindt, M.R., Marcotte, T.D., Heaton, R.K., Ellis, R.J., Grant, I., 2005. Effects of methamphetamine dependence and HIV infection on cerebral morphology. *American Journal of Psychiatry* 162, 1461–1472.
- Kohler, E., Keysers, C., Umiltà, M.A., Fogassi, L., Gallese, V., Rizzolatti, G., 2002. Hearing sounds, understanding actions: action representation in mirror neurons. *Science* 297, 846–848.
- Kruesi, M.J., Casanova, M.F., Mannheim, G., Johnson-Bilder, A., 2004. Reduced temporal lobe volume in early onset conduct disorder. *Psychiatry Research* 132, 1–11.
- Laakso, M.P., Vaurio, O., Koivisto, E., Savolainen, L., Eronen, M., Aronen, H.J., Hakola, P., Repo, E., Soininen, H., Tiihonen, J., 2001. Psychopathy and the posterior hippocampus. *Behavioural Brain Research* 118, 187–193.
- Laakso, M.P., Gunning-Dixon, F., Vaurio, O., Repo-Tiihonen, E., 2002. Prefrontal volumes in habitually violent subjects with antisocial personality disorder and type 2 alcoholism. *Psychiatry Research* 114, 95–102.
- Lapierre, D., Braun, C.M.J., Hodgins, S., 1995. Ventral frontal deficits in psychopathy: neuropsychological test findings. *Neuropsychologia* 33, 139–151.
- Liu, X., Matochik, J.A., Cadet, J.L., London, E.D., 1998. Smaller volume of prefrontal lobe in polysubstance abusers: a magnetic resonance imaging study. *Neuropsychopharmacology* 18, 243–252.
- Lyoo, I.K., Pollack, M.H., Silveri, M.M., Ahn, K.H., Diaz, C.I., Hwang, J., Kim, S.J., Yurgelun-Todd, D.A., Kaufman, M.J., Renshaw, P.F., 2006. Prefrontal and temporal gray matter density decreases in opiate dependence. *Psychopharmacology (Berlin)* 184, 139–144.
- Moll, J., Eslinger, P.J., Oliveira-Souza, R., 2001. Frontopolar and anterior temporal cortex activation in a moral judgement task: preliminary functional MRI results in normal subjects. *Arquivos de Neuro-Psiquiatria* 59, 657–664.
- Moffitt, T.E., 1993. Adolescence-limited and life-course-persistent antisocial behavior: a developmental taxonomy. *Psychological Bulletin* 100, 674–701.
- Paulus, M.P., Rogalsky, C., Simmons, A., Feinstein, J.S., Stein, M.B., 2003. Increased activation in the right insula during risk-taking decision making is related to harm avoidance and neuroticism. *Neuroimage* 19, 1439–1448.
- Pridmore, S., Chambers, A., McArthur, M., 2005. Neuroimaging in psychopathy. *Australian and New Zealand Journal of Psychiatry* 39, 856–865.
- Raine, A., Lencz, T., Bihle, S., LaCasse, L., Colletti, P., 2000. Reduced prefrontal gray matter volume and reduced autonomic activity in antisocial personality disorder. *Archives of General Psychiatry* 57, 119–127.
- Raine, A., Lencz, T., Taylor, K., Hellige, J.B., Bihle, S., Lacasse, L., Lee, M., Ishikawa, S., Colletti, P., 2003. Corpus callosum

- abnormalities in psychopathic antisocial individuals. *Archives of General Psychiatry* 60, 1134–1142.
- Schroeder, M.L., Schroeder, K.G., Hare, R.D., 1985. Generalizability of a checklist for the assessment of psychopathy. *Journal of Consulting and Clinical Psychology* 51, 511–516.
- Sterzer, P., Stadler, C., Poustka, F., Kleinschmidt, A., 2005a. Aggressive behavior in adolescents is associated with reduced grey matter in anterior insular cortex. Paper Presented at the Meeting of Deutsche Gesellschaft für Psychiatrie, Psychotherapie and Nervenheilkunde. Berlin.
- Sterzer, P., Stadler, C., Krebs, A., Kleinschmidt, A., Poustka, F., 2005b. Abnormal neural responses to emotional visual stimuli in adolescents with conduct disorder. *Biological Psychiatry* 57, 7–15.
- Thompson, P.M., Hayashi, K.M., Simon, S.L., Geaga, J.A., Hong, M.S., Sui, Y., Lee, J.Y., Toga, A.W., Ling, W., London, E.D., 2004. Structural abnormalities in the brains of human subjects who use methamphetamine. *Journal of Neuroscience* 24, 6028–6036.
- Tiihonen, J., Hakola, P., 1994. Psychiatric disorders and homicide recidivism. *American Journal of Psychiatry* 1561, 436–438.
- Tiihonen, J., Hodgins, S., Vaurio, O., Laakso, M., Repo, E., Soininen, H., Aronen, H.J., Nieminen, P., Savolainen, L., 2000. Amygdaloid volumes loss in psychopathy. Society for Neuroscience 2000 Annual Meeting, New Orleans, La, November 4–9.
- Vollm, B.A., Taylor, A.N., Richardson, P., Corcoran, R., Stirling, J., McKie, S., Deakin, J.F., Elliott, R., 2006. Neuronal correlates of theory of mind and empathy: a functional magnetic resonance imaging study in a nonverbal task. *Neuroimage* 29, 90–98.
- Wechsler, D., 1981. Adult Intelligence Scale. Psychological Corporation, San Antonio, TX, USA.
- Yang, Y., Raine, A., Lencz, T., Bihrlle, S., LaCasse, L., Colletti, P., 2005. Volume reduction in prefrontal gray matter in unsuccessful criminal psychopaths. *Biological Psychiatry* 57, 1103–1108.